

WINTER 2023-2024



Quarterly  
**Newsletter**

**Ankylosis and  
Retained Primary Teeth**

Provided by:

**STRICKLAND**  
**ORTHODONTICS**

---

improving life, one SMILE at a time

Quarterly

# Newsletter



Provided by: Strickland Orthodontics

WINTER 2023-2024

## Dear Baldwin County Dental Offices:

Here at Strickland Orthodontics, we have decided to start doing a newsletter for our local dentists! We want to keep y'all up to date with any big news involving our practice and send over a couple of our most exciting finished cases. We also wanted to use this opportunity to summarize a few relevant articles to help us all care for our patients in a more evidence based way! We hope that you all enjoy this, and we look forward to serving the Eastern Shore community alongside you. We have included Dr. Stephen's and Dr. Maggie's cell phone numbers at the bottom of the page. Please reach out to them directly with any concerns, questions, or to have treatment planning conversations.

## Table of Contents:

Ankylosis

Patient Examples

Case Studies

Doctor's Corner

Strickland  
Happenings

### Dr. Stephen Strickland

Diplomate, American Board of Orthodontics



CELL: 251-391-7568

### Dr. H. Len Strickland



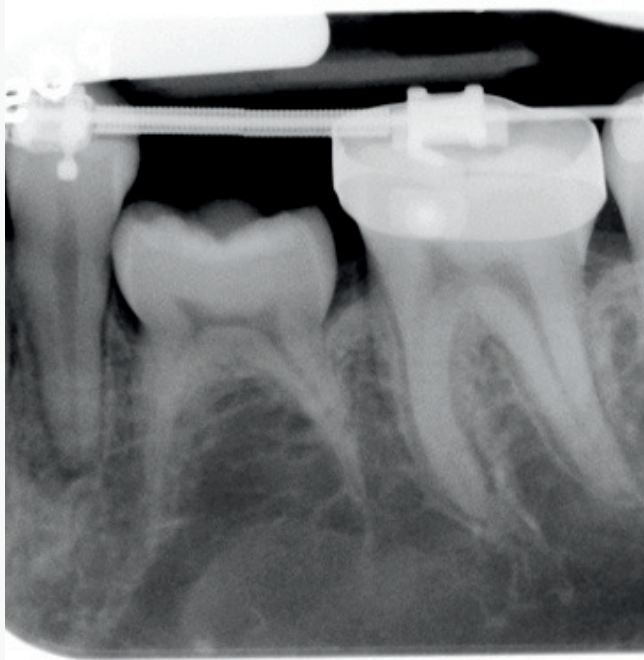
### Dr. Maggie Grissom

Diplomate, American Board of Orthodontics



CELL: 256-343-6604





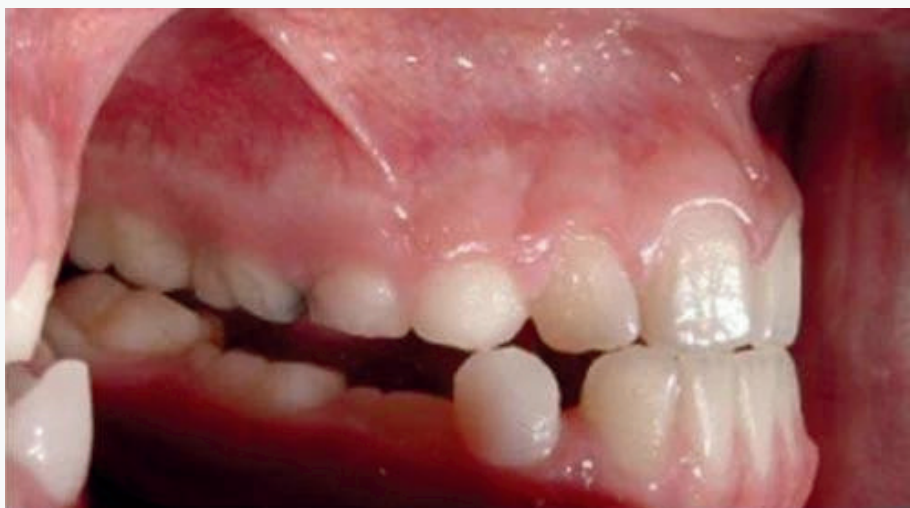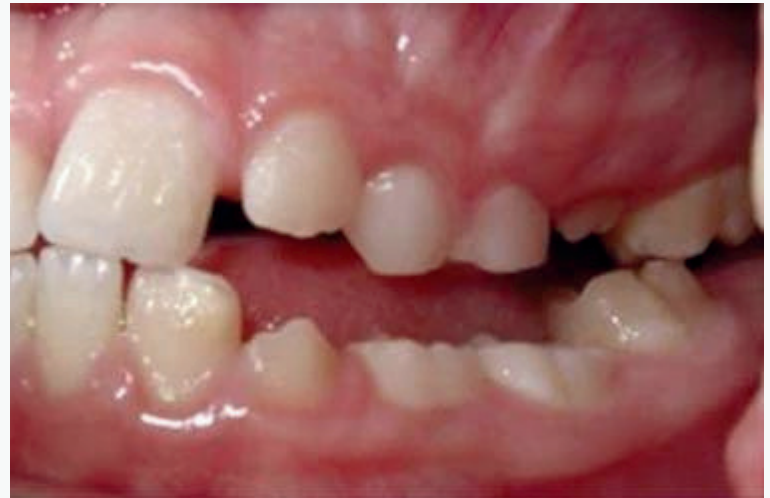## WHAT IS ANKYLOSIS?

Ankylosis or fusion between the cementum of the root and the surrounding bone leads to an eruptive abnormality. The tooth cannot properly erupt into occlusion or exfoliate if it is a primary tooth. A study published in 2018, reports that 65.7% of subjects with premolar agenesis also had ankylosis of primary molars and considered that hypodontia represents a possible etiological factor in ankylosis of these molars.

Deciduous teeth become ankylosed far more frequently than do permanent teeth, the ratio being better than 10 to 1, and lower teeth are ankylosed more than twice as often as upper teeth ([Beresescu, 2022](#)).

## WHY IS THIS A PROBLEM?

"Without timely and effective treatment, an infraerupted tooth can result in insufficient development of adequate width and height of supporting bone. This can complicate future dental treatment including placement of a dental implant and orthodontics. Insufficient bone may also result in dehiscences, periodontal pocketing, and root exposure of the adjacent teeth. The infraerupted tooth and adjacent teeth are also at an increased risk of developing a carious lesion due to plaque accumulation surrounding the crown and difficult access for proper oral hygiene" (Wiltshire, 2007).



## WHAT DO WE DO ABOUT IT?

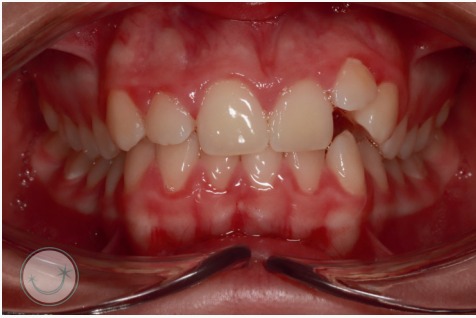"If there is no permanent successor, most authors recommend early extraction followed by orthodontic treatment to close the space and prevent the formation of a bony defect" (Wiltshire, 2007). If space closure with orthodontic treatment is not recommended or completed, the patient can work with their restorative dentist to plan potential grafting prior to implant placement or look into the option of a bridge.

## Patient Examples

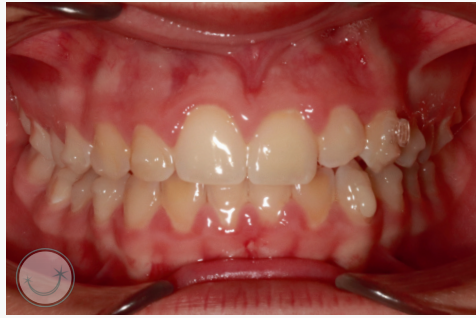Below you will find some cases related to the topic of "Ankylosis" that will hopefully give you some insight into how we approach these cases and why we value the communication between our offices regarding treatment plans.

**1**

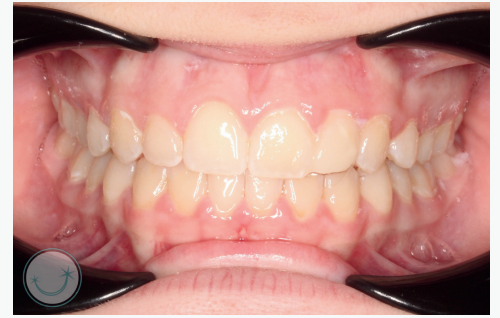Ankylosed UL2 (#10); case completed with Invisalign



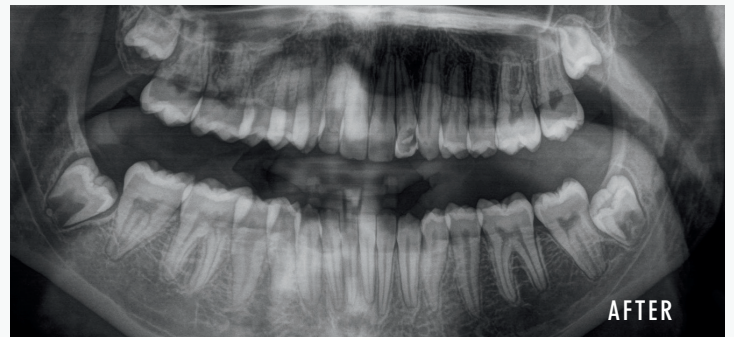
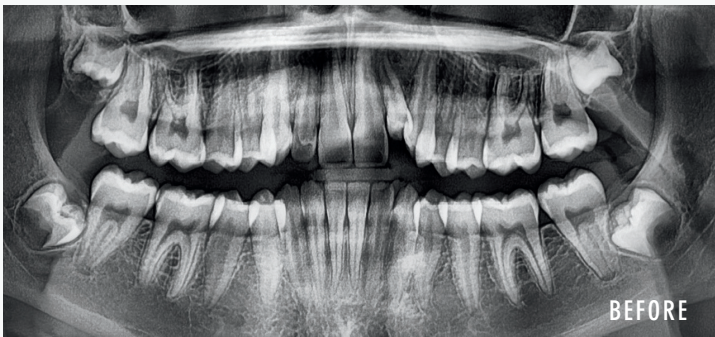
Initial photo



Progress - lateral stopped moving at this point

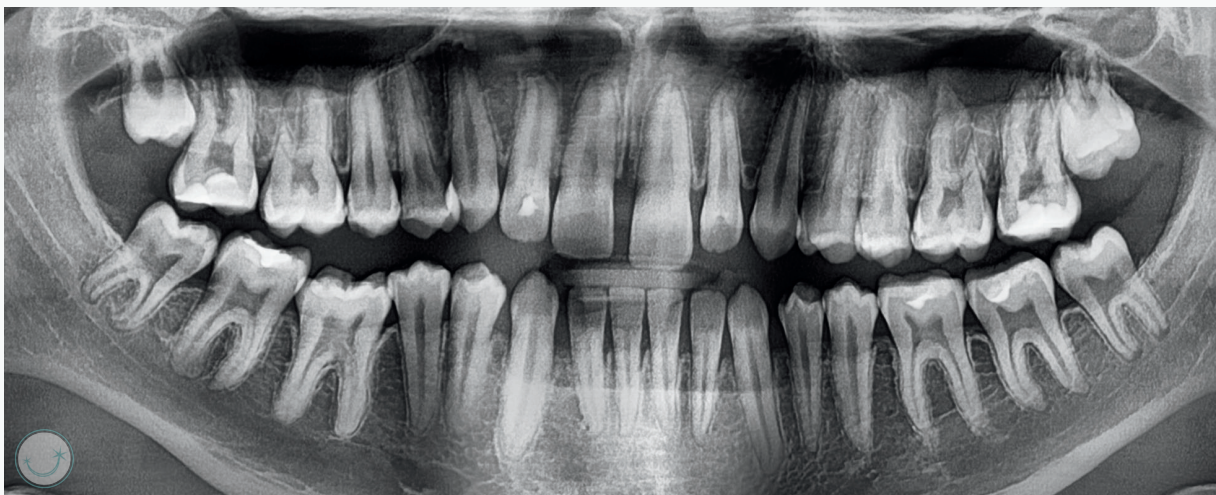

Final - added cosmetic bonding to UL2 (#10) to disguise



**2**

Ankylosed LR6 (#30) - attempted to bring in with limited fixed appliances. Plan: #30 to be extracted. Offered TAD protraction of LR7/8 (#31/32) - patient declined. Invisalign treatment not yet complete.

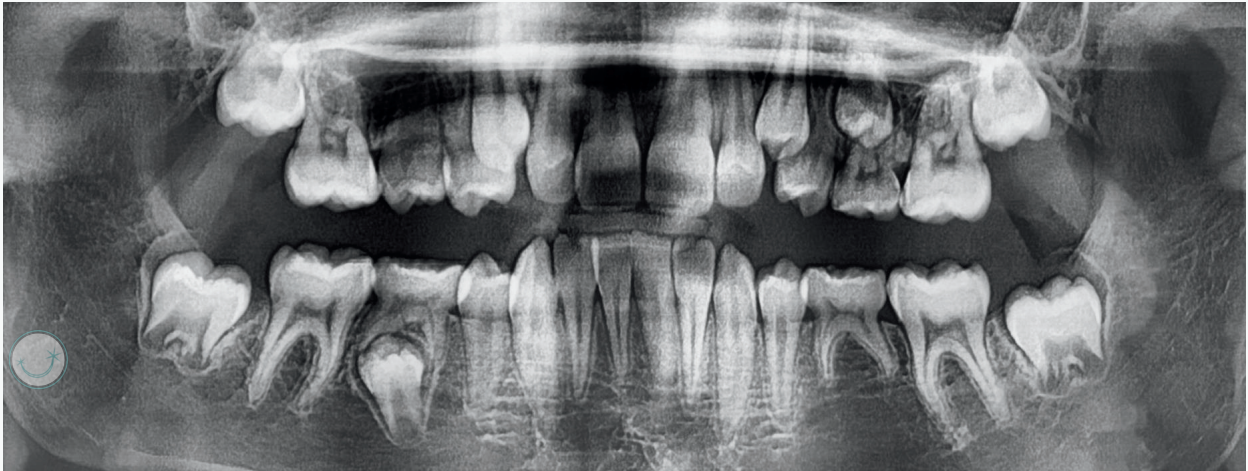




## Examples in Observation Patients

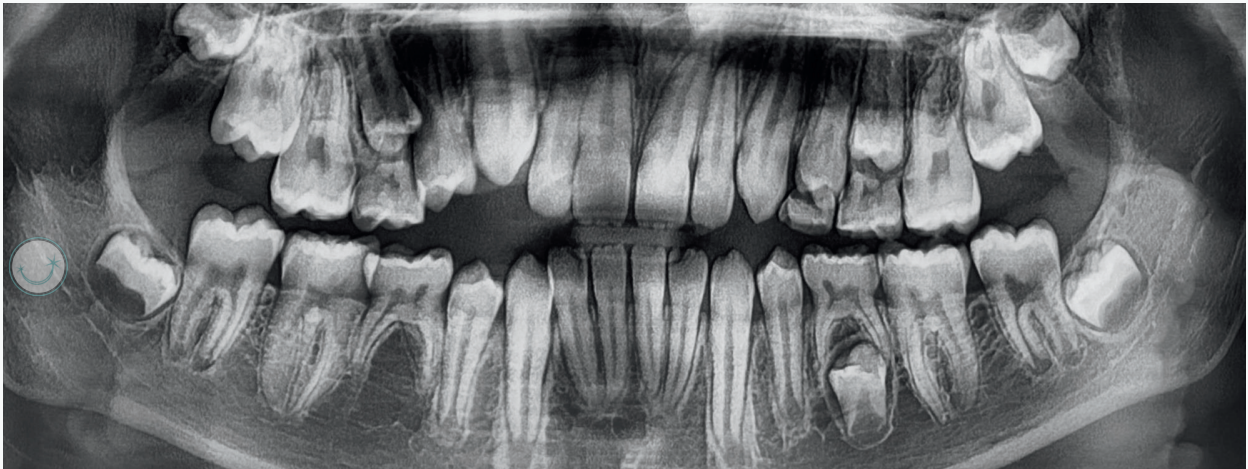
3

Good looking LLE (#K) and no 3rd molar. No signs of ankylosis at this point. TAD protraction isn't as helpful for these patients if a third molar is not present. Looking to hold onto LLE (#K) as long as possible. Continue to monitor at observation appointments.



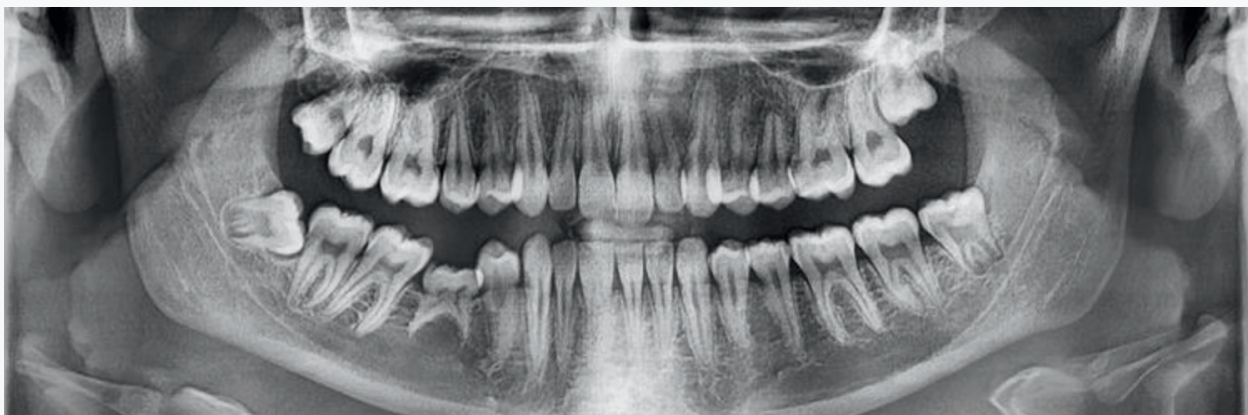
4

Good looking LRE (#T), has #32. No signs of ankylosis at this point. TAD protraction would be indicated in this case since a third molar is present. The patient/parent will be presented options to remove LRE (#T)/TAD protract or to hold onto the LRE for as long as possible and monitor development of ankylosis.



5

Ankylosed LRE (#T)- needs to be removed as soon as possible followed by restorative conversation. Not a great case for TAD protraction because the LR8 (#32) is unlikely to be functional. Can still do TAD protraction if patient/parent are aware that UR7 (#2) may be out of occlusion.

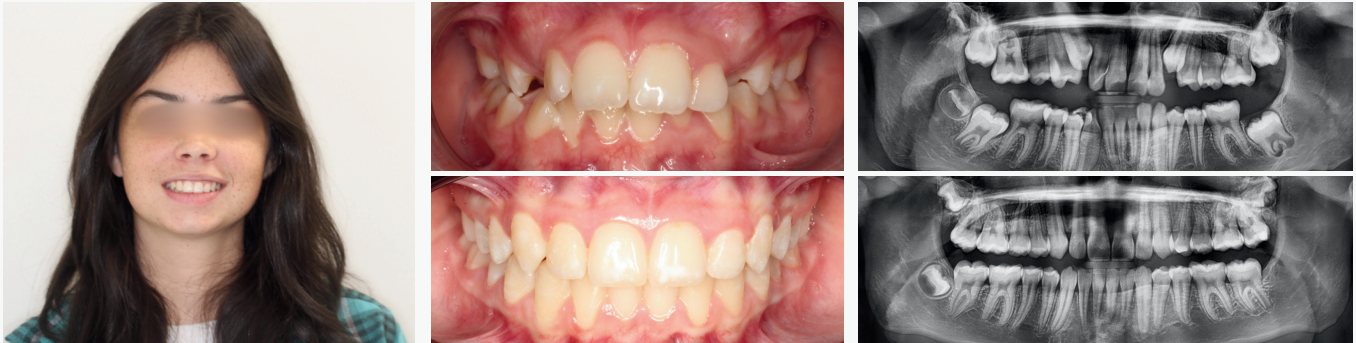



## Recently Finished Cases

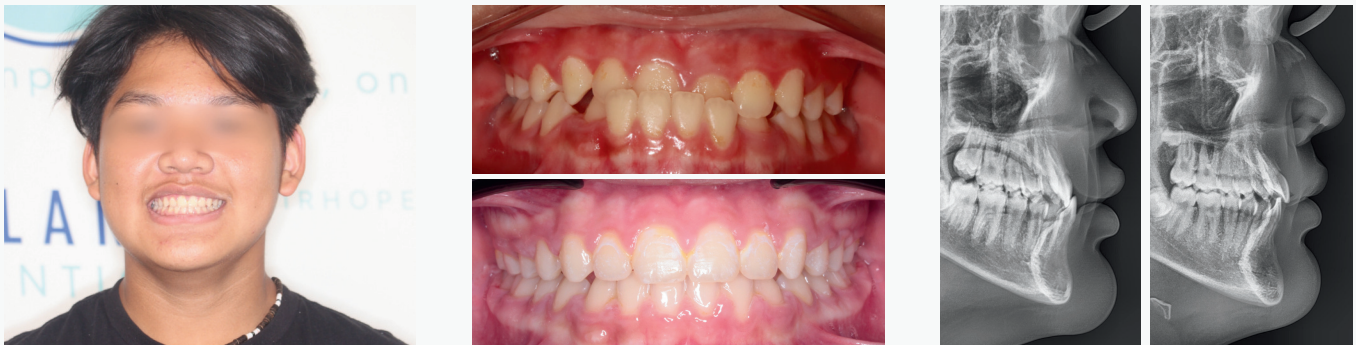1

Class II, moderate crowding treated with expander and braces



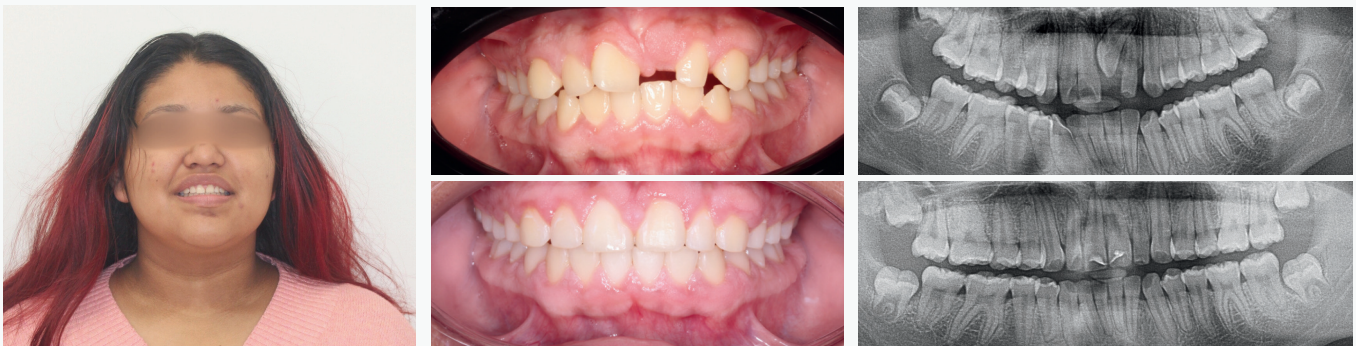2

Class III correction treated with braces



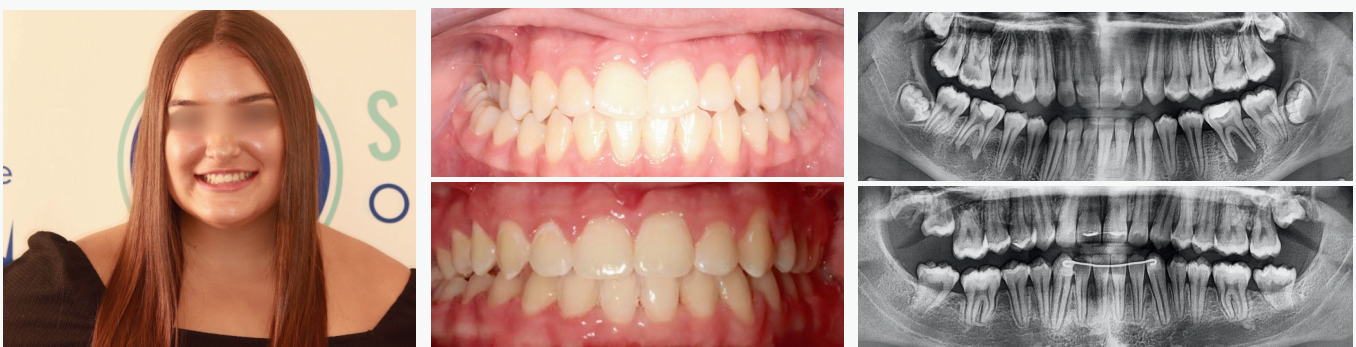3

Impacted #9 treated with surgical exposure and braces



4

Plan involved extraction of three first molars (#3, #19, #30) due to decay; closed first molar space with TADs





## Doctor's Corner

Hello everyone! I hope all have had a great Holiday Season! I have loved hearing from our patients all of the fun things they have been up to on their break. Lots of travel and sleeping in! I recently joined Impact 100, and at a recent event, they had a panel of physicians of varying specialties come speak. A local neurologist spoke on ways to keep our minds sharp as we age and mentioned trying new things as a way to "stay fresh". If you have always been an avid reader, try playing mahjong. If you love to go on walks, maybe pick up tennis or golf. She talked about challenging our bodies and minds physically, emotionally, and socially by taking part in some different activities than we are accustomed to. Let's all try something different in the new year that is upon us! Cheers to 2024!

## Dr. Maggie Grissom

Diplomate, American Board of Orthodontics



A few recent favorite books of mine!

Lessons in  
Chemistry

By: Bonnie Garmus

The Winemakers  
Wife

By: Kristin Harmel

I Will Find You

By: Harlan Coben

## Strickland Happenings



We had such a great time at the Fairhope's Magical Christmas Parade again this year. We are blessed to live in such a great community, and we love any opportunity to get out and support our area.

Springtime always brings a few 5Ks that we look forward to participating in each year. You can catch us at Pirate Dash, Gator Chase, and maybe a few others!

### Follow Us!



Strickland Orthodontics



@stricklandorthodontics



@strickland\_orthodontics

H Len Strickland DDS

Maggie Grissom DMD MSD

Diplomate, American Board of Orthodontics

Stephen Strickland DMD MS

Diplomate, American Board of Orthodontics

Fairhope: 7489 Parker Road | 251.928.9292

Fairhope South: 19059 South Greeno Road | 251.928.9292

Spanish Fort: 9816 Millwood Circle | 251.272.3232

Bay Minette: 1901 Hand Ave. | Foley: 815 North Alston St.

Email: [Smile@StricklandOrthodontics.com](mailto:Smile@StricklandOrthodontics.com) | Text: 251.272.3232

improving life, one SMILE at a time