



WINTER 22-23

Quarterly  
**Newsletter**

Provided by:

**STRICKLAND**  
**ORTHODONTICS**

---

improving life, one SMILE at a time

Quarterly

# Newsletter



Provided by: Strickland Orthodontics

Winter 22-23

## Dear Baldwin County Dental Offices:

Here at Strickland Orthodontics, we have decided to start doing a newsletter for our local dentists! We want to keep y'all up to date with any big news involving our practice and send over a couple of our most exciting finished cases. We also wanted to use this opportunity to summarize a few relevant articles to help us all care for our patients in a more evidence-based way! We hope that you all enjoy this, and we look forward to serving the Eastern Shore community alongside you. We have included Dr. Stephen and Dr. Maggie's cell phone numbers at the bottom of the page. Please reach out to them directly with any concerns, questions, or to have treatment planning conversations.

## Table of Contents:

**Topic: Retention**

**Patient Examples**

**Case Studies**

**Strickland Happenings**

**Doctor's Corner**

## Dr. Stephen Strickland

Diplomate, American Board of Orthodontics



## Dr. H. Len Strickland



## Dr. Maggie Grissom

Diplomate, American Board of Orthodontics







## RETENTION

This quarter we wanted to focus on retainers. Depending on each patient's orthodontic treatment and growth pattern, a certain type of retainer might be better for them. If there is a retainer option that is better for a patient, we will make our recommendation, but we also want the patient to be involved in the decision-making process. It is ultimately up to them to ensure proper retainer wear and care. Per the article "How do general dental practitioners perceive and deal with orthodontic bonded retainers?" (Bolender, 2021), approximately 67% of dentists are interested in continuing education on orthodontic retention, and dentists do not believe they are well-informed on the retention phase by their orthodontist peers. We thought this would be a good way to help educate and get on the same page to better treat our patients together in the retention phase of their orthodontic care.

### Our typical recommendations:

#### Thermoplastic Retainers:

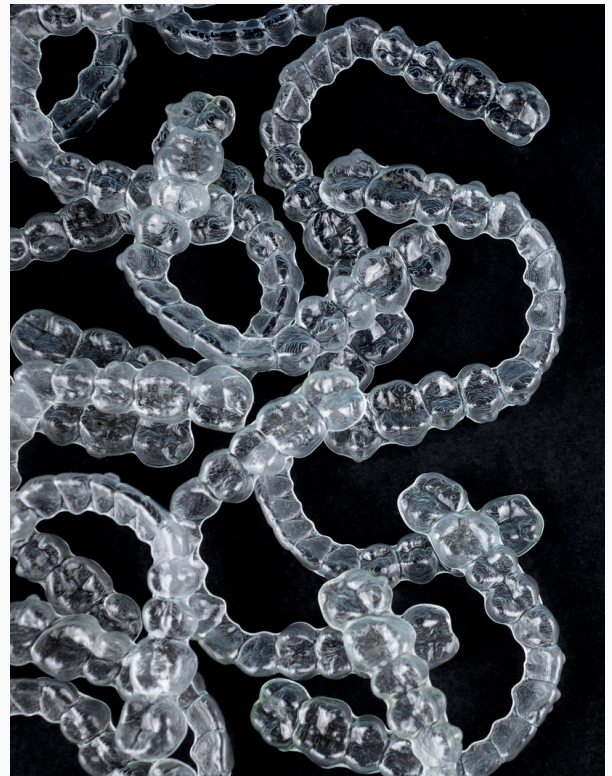- Material: Taglus Tuff
- Recommend for most patients. Wear for 2 weeks full-time and then transition into 12 hours per day for life. Nighttime for a lifetime!
- To be worn even if fixed retainers are present
- Clear retainers need to be replaced

#### Upper Fixed Retainer:

- Material: Retanium (Titanium Molybdenum Alloy)
- Across central incisors or across lateral to lateral
- When indicated: If a patient started with large diastema or anterior spacing

#### Lower Fixed Retainer:

- Material: gold plated stainless steel with pads on lower cuspids. Only bonded to lower cuspids for improved hygiene unless there is a problem tooth we are concerned about moving during the 12 hours that the patient is not wearing the thermoplastic retainer.
- When indicated: if severe crowding present prior to treatment or by request from patient or parent.



Summary: We typically recommend clear thermoplastic retainers and are selective about recommending fixed retainers. Patients only have them upon request or if the doctor strongly recommends them! If recommended, we want fixed retainers to stay on for life! Retainers require maintenance, whether they are fixed or removable. Please help us encourage our patients to prioritize this and come see us for any needs!!

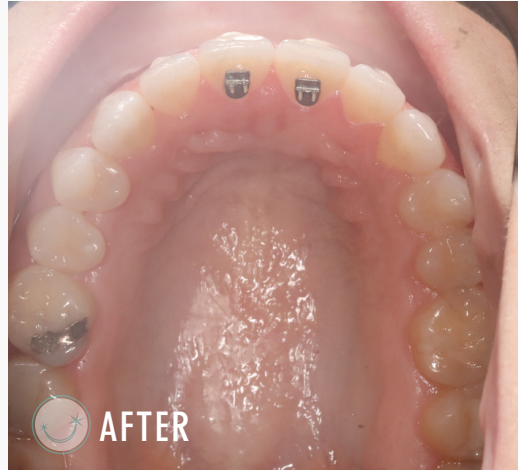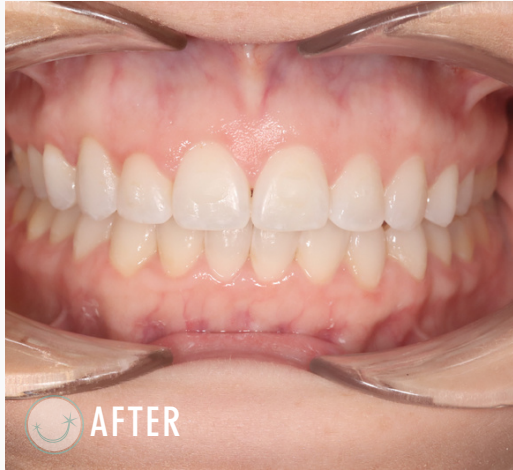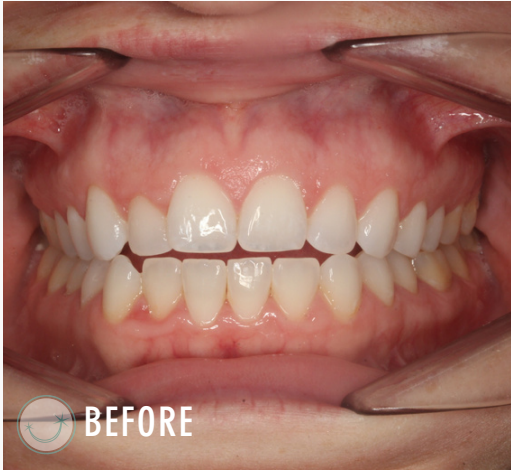Below you will find some cases and literature related to the topic of "Retention" that will hopefully give you some insight into why we recommend certain retainers and things to look out for in your patients post-orthodontically.



## Case Studies

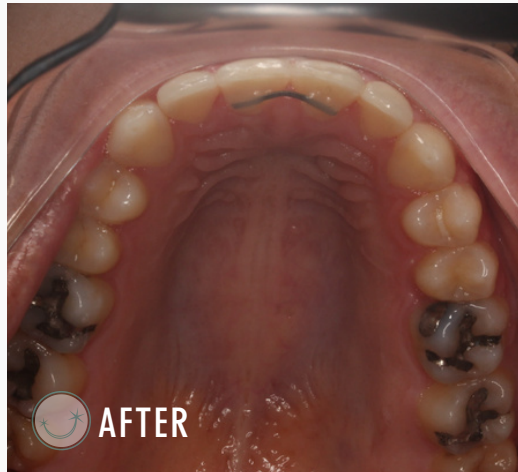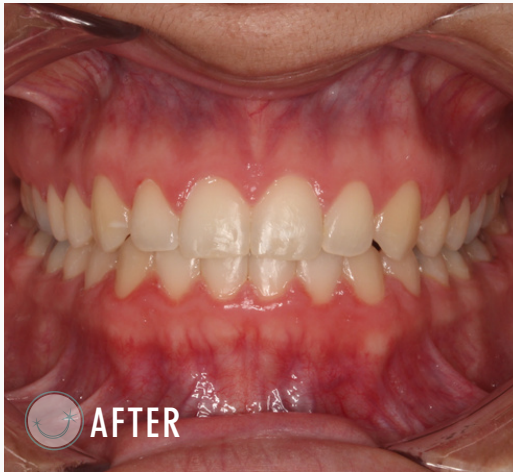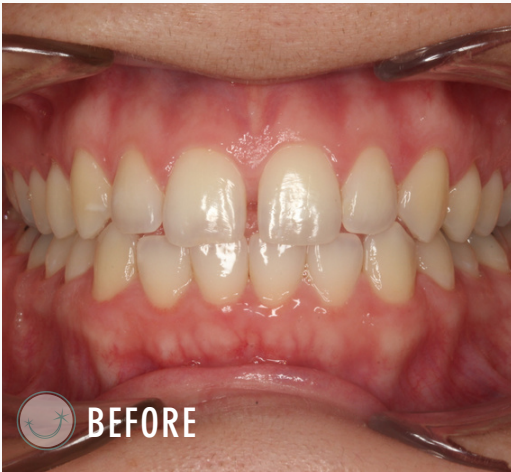**1**

Open Bite / Retention Plan: History of tongue thrust habit. Bond tongue reminders U1s to help with habit and to maintain closure of open bite. Hard to see but we left 20% of U2-2 attachments present to help retain closure of open bite. Will eval in 3 months to see how habit is doing/if ready to remove attachments and tongue reminders.



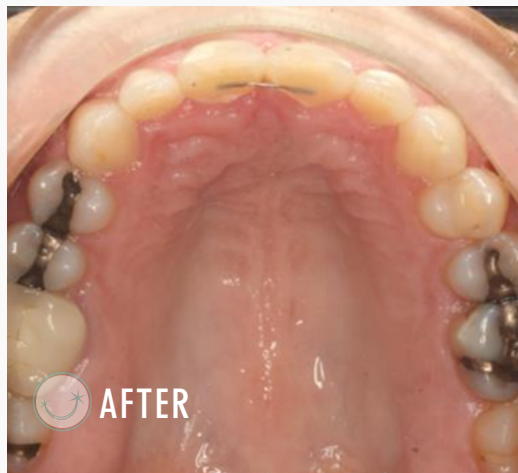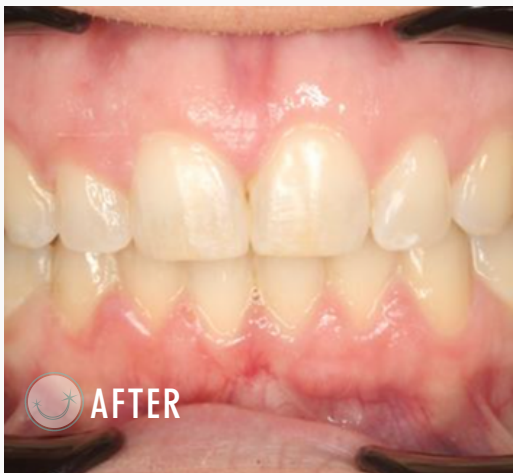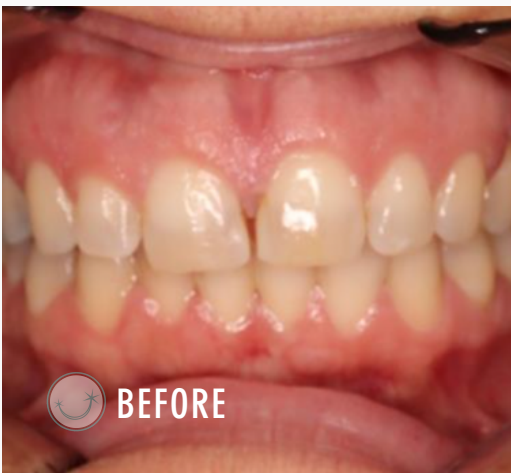**2**

Example of need for a fixed upper retainer.



**3**

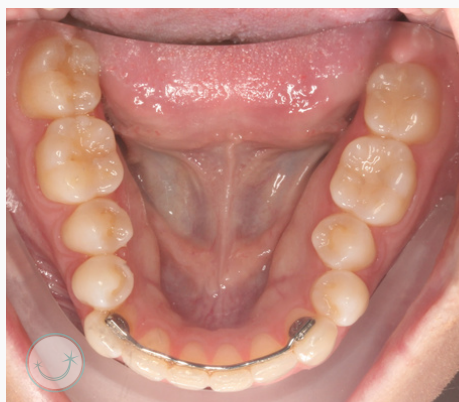Second example of need for a fixed upper retainer.





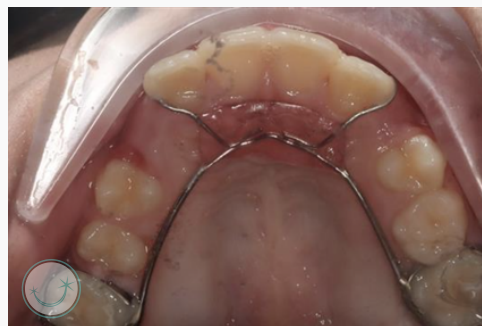## Case Studies

4



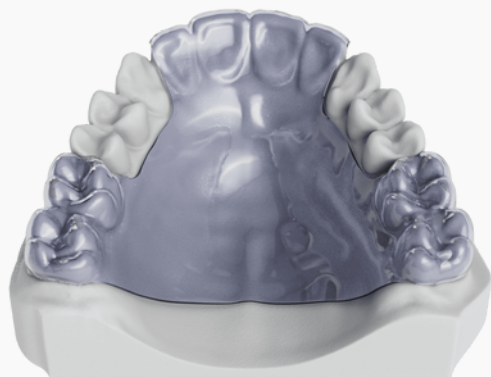
Example of why L3-3 is not enough on its own. L3-3 was placed by previous orthodontist and thermoplastic retainer wear was not consistent. Anterior teeth have remained relatively straight while the rest of the arch has relapsed significantly.

5



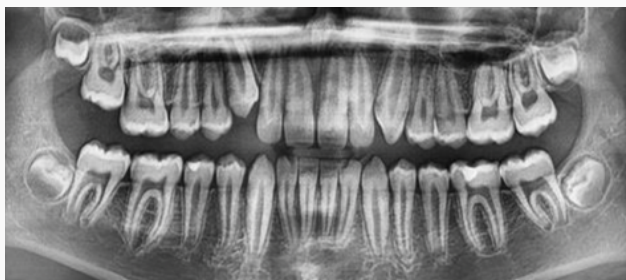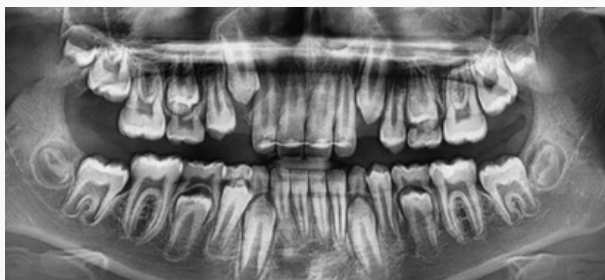Example of a non-compliant phase 1 retainer. We are able to hold expansion and keep space from returning around upper incisors.

6



Our typical phase I retainer for complaint patients. We will double the layer of plastic in the posterior if the patient had expansion performed to help maintain the transverse. We will monitor regularly and ask patient to let us know if any newly erupting teeth cause an interference. We can typically adjust the retainer for comfort until comprehensive treatment is recommended.

7



Previous phase I treatment with another orthodontist. UR3 (#6) was starting to overlap UR2 (#7). We removed the fixed retainer and made a thermoplastic retainer. This allowed the lateral root to have some freedom to shift mesial in order to allow the canine to erupt. We prefer not to use fixed retainers in the mixed dentition for this reason.

## Literature

1

### Effectiveness of lingual retainers bonded to the canines in preventing mandibular incisor relapse

Anne-Marie Renkema 1, Samah Al-Assad, Ewald Bronkhorst, Sabine Weindel, Christos Katsaros, Jörg A Lisson

"The 3-3 mandibular lingual stainless steel retainer (bonded to the canines only) is effective in preventing relapse in the mandibular anterior region in most patients, but a relatively high percentage will experience a small to moderate increase in mandibular incisor irregularity."

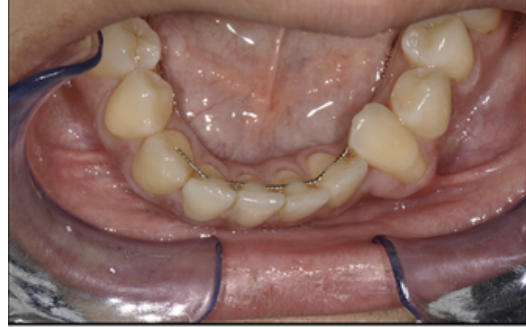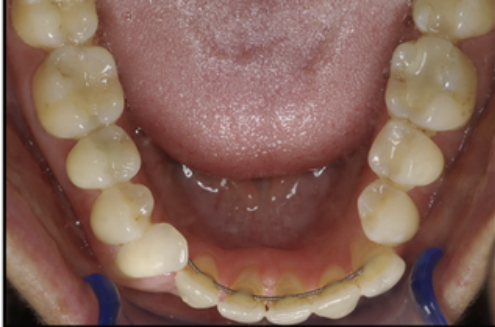**This is why we provide and strongly recommend wear of clear retainers for life over fixed retainers! Bonded retainers are not enough!**

2

### Inadvertent tooth movement with fixed lingual retainers

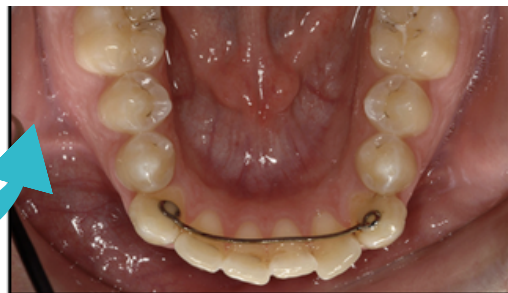Timothy G. Shaughnessy,<sup>a</sup> William R. Proffit,<sup>b</sup> and Said A. Samarc

- No single fixed retainer type appears to be immune to unexpected and unwanted tooth movement, although tooth movement is more likely when more flexible wires are used.
- Small-diameter flexible spiral wires bonded to each tooth pose the greatest risk for creating significant inadvertent tooth movement (ie torque discrepancies) and resulting complications. See below:



- It has been shown that a higher percentage of patients with fixed retainers secured only to the canines will have incisor irregularity at 5 years after treatment than if the retainer wire is bonded to the incisors as well.
- However, early detection of bonding failures, wire breakage, and tooth movement created by the retainer is critical in preventing major problems.

What we use! We feel like cleanability and stability of this retainer is best! The higher chance of incisor irregularity is communicated to patients, and they are required to wear clear over to help prevent this!



**Let us know if this happens!**



## Doctor's Corner

I hope everyone had a very Merry Christmas and a Happy New Year! We have been Fairhope residents for 6 months now and are loving every second. I am glad that I have had the chance to meet several of you and look forward to connecting with everyone in the future. One of my favorite things to do in the new year is to chose a word that I want to focus my attitude and energy towards. It has been a good way for me to start the new year with intention- I encourage you to try it if you don't already do this! This year my word is gratitude! I am excited to continue changing lives one smile at a time! Cheers to 2023!!

## Dr. Maggie Grissom

Diplomate, American Board of Orthodontics



As I did last quarter, here are three of my favorite books. I hope that there is something for everyone!

### Educated

By: Tara Westover

A story of determination to receive what we all have been so fortunate to obtain, an education.

### How to Win Friends and Influence People

By: Dale Carnegie

An oldie but goodie! Always helpful to revisit these principles.

### The Great Alone

By: Kristen Hannah

I have a soft spot for historical fiction!

## Strickland Happenings



Pumpkin Decorating Contest

Congrats to Malbis Parkway Pediatric Dentistry for winning our pumpkin decorating contest! We'd also like to thank all of the offices that participated. We had some really cute entries!



Fairhope Christmas Parade

We had a \*magical\* night at the 2022 Christmas parade through downtown Fairhope! This group of tooth fairies is so thankful for the support of our community and referring doctors!



Employee Spotlight:

We want to congratulate Courtney on the birth of a beautiful baby girl! We will surely miss her while she's on maternity leave, but we wish her all the best!

H Len Strickland DDS

Maggie Grissom DMD MSD

Diplomate, American Board of Orthodontics

Stephen Strickland DMD MS

Diplomate, American Board of Orthodontics

Fairhope: 7489 Parker Road | 251.928.9292

Fairhope South: 19059 South Greeno Road | 251.928.9292

Spanish Fort: 9816 Millwood Circle | 251.272.3232

Bay Minette: 1901 Hand Ave. | Foley: 815 North Alston St.

Email: [Smile@StricklandOrthodontics.com](mailto:Smile@StricklandOrthodontics.com) | Text: 251.272.3232

improving life, one SMILE at a time